Introducing New Gamma Knife ICON at Research Medical Center

Gamma Knife Icon Overview:

1.1 History of Gamma Knife at Research Medical Center

1.2 Stereotactic Radiosurgery, How the Gamma Knife Works

1.3 Conditions Treated with Gamma Knife

- Metastatic Brain Cancer
- Acoustic Neuroma
- Trigeminal Neuralgia
- Arteriovenous Malformations
- Other Brain Tumors
- Tremor

1.4 Your Physician Partners and Gamma Knife Team

1.5 How to refer a patient for consultation

History of Gamma Knife and new ICON

1.1

- ✓ First used in 1968, has been used to treat more that one million patients
- ✓ Research Medical Center treated first patients in 1994
- ✓ Treated more than 2,000 patients at Research Medical Center
- ✓ Only facility in region, one of only 17 in the nation with the Gamma Knife ICON
- ✓ New ICON offers neurosurgeon expansion into new treatment areas

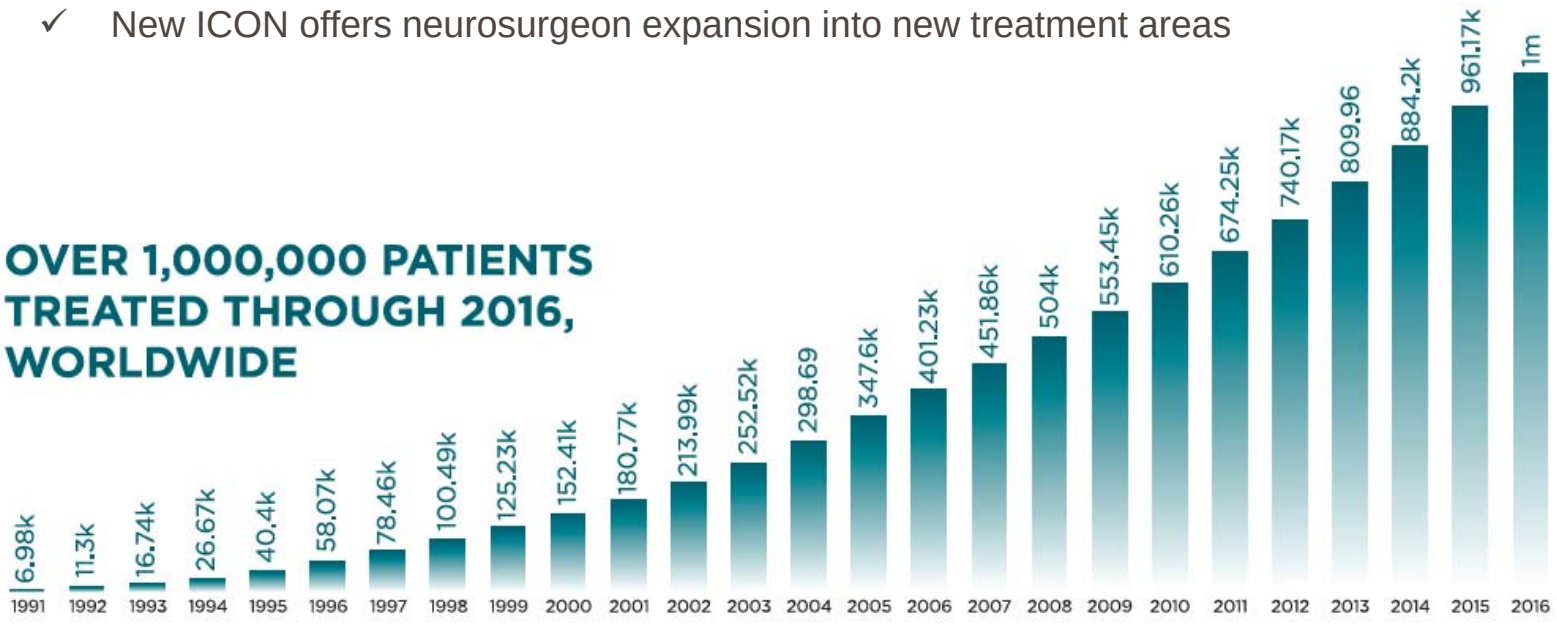

How does the Gamma Knife Work?

1.2 a

- Alternate to conventional open skill brain surgery and traditional radiation therapy
- Is the most advanced cranial stereotactic radiosurgery
- A sophisticated system to treat brain conditions without incisions, general anesthesia or an overnight hospital stay
- Effective to treat some lesions in difficult-to-access areas
- Delivers high dose radiation to a small / critically located target in brain

Gamma Knife ICON:

1.2 b

- Up to 192 radiation beams intersect at single point

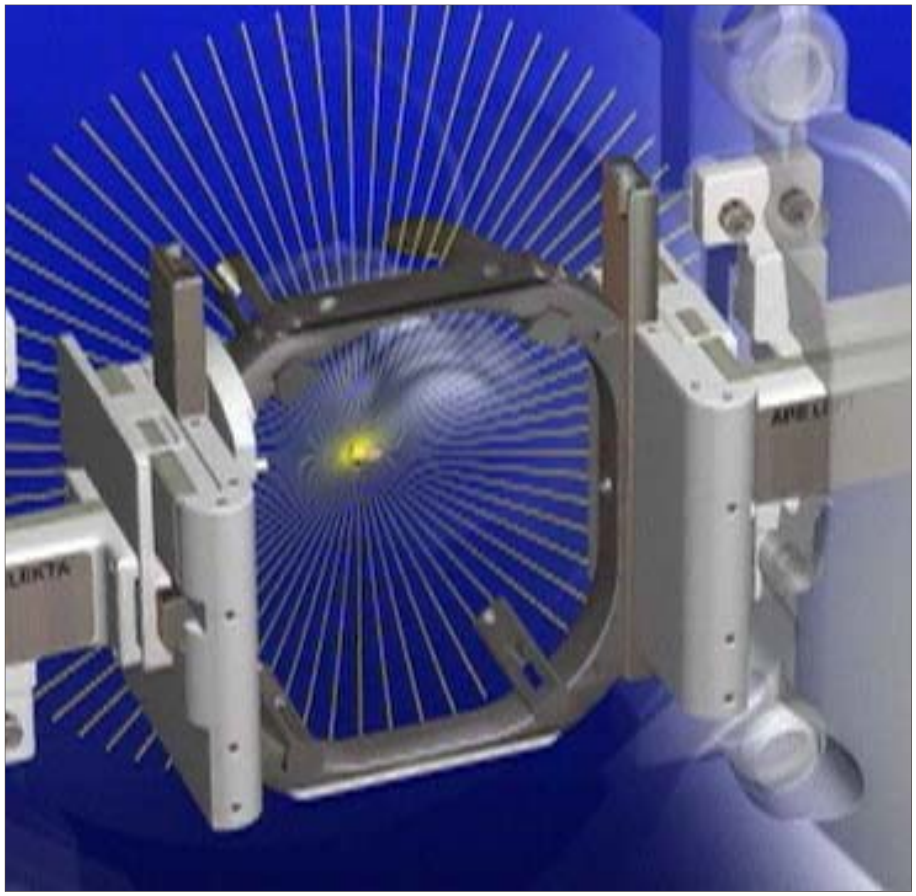

Gamma Knife ICON:

1.2 c

- With Icon, dose to normal brain is 2-4 times lower than stereotactic radiosurgery, extracranial dose
  10 – 130 times less

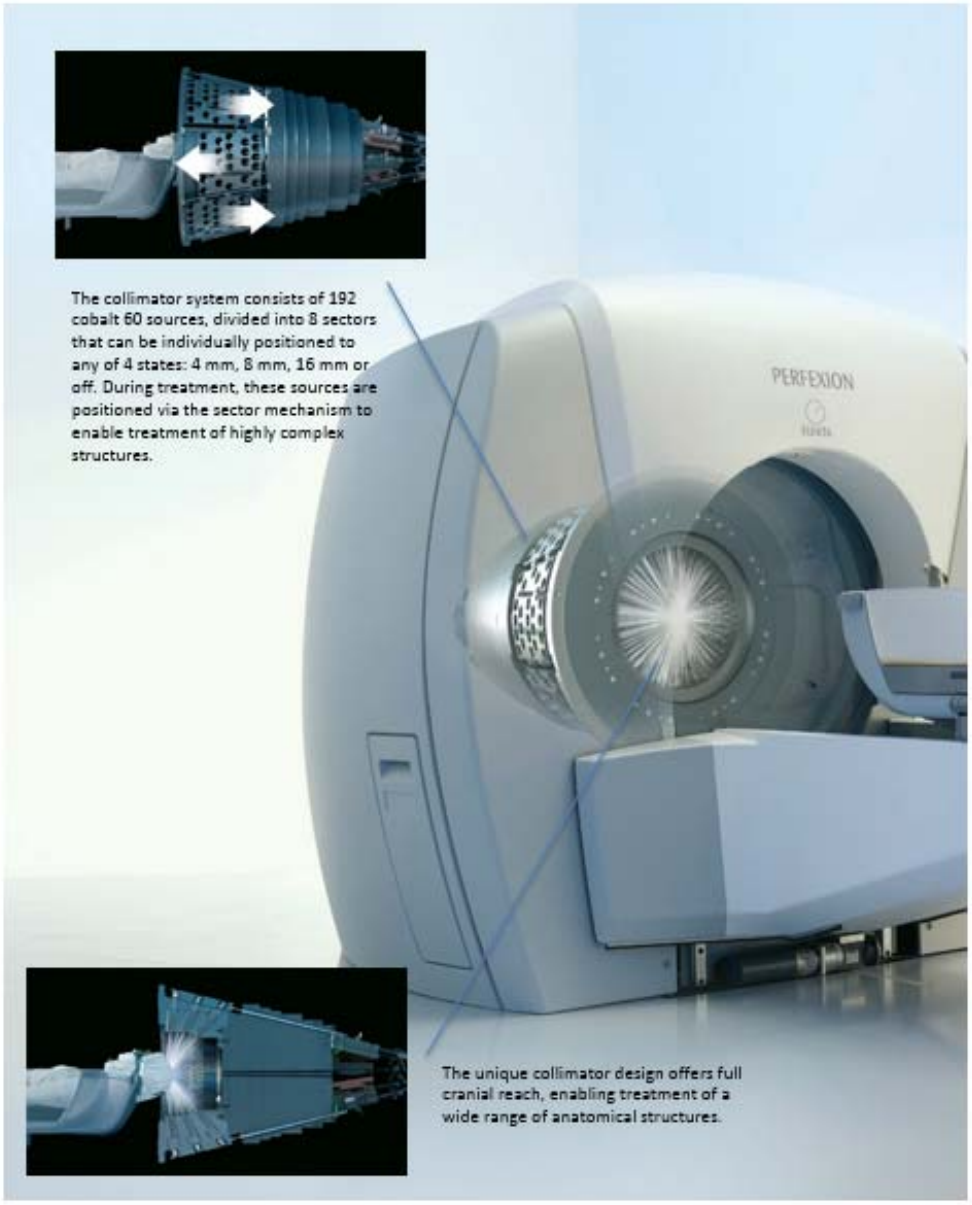

Stereotactic Radiosurgery

1.2 d

- Motion Management system monitors the patient in real time
- 0.15 accuracy, six times better than industry standard
- If the patient moves outside of the pre-set threshold, the system's gating functionality instantly blocks the radiation.

Conditions We Treat:

1.3

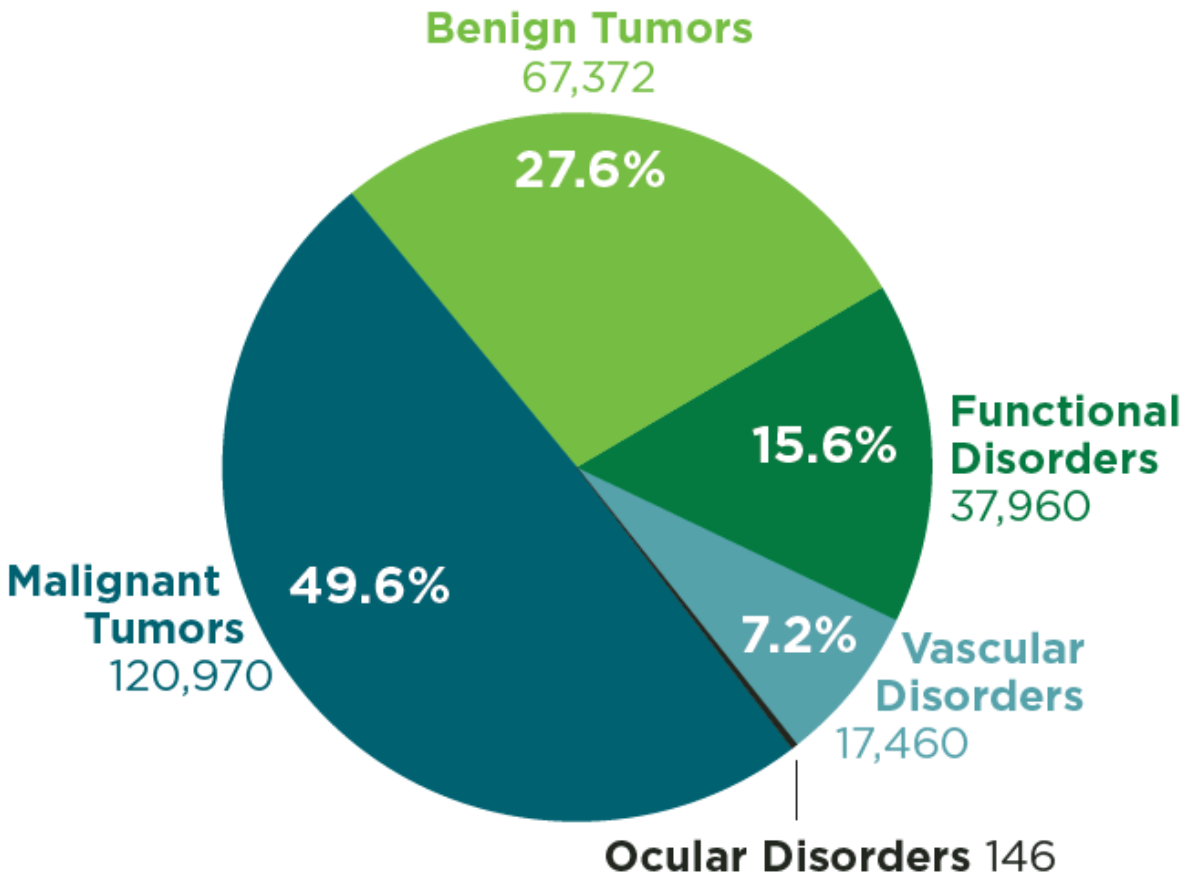

Metastatic Brain Cancer

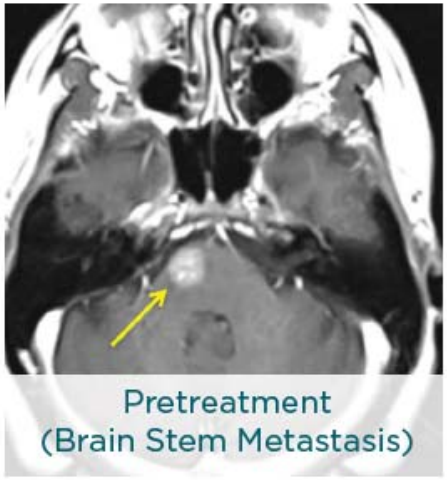

- All tumor histologies including radioresistant tumors such as melanoma and renal cell carcinoma
- Patients with surgically inaccessible tumors
- Patients with multiple lesions
- Recurrent or new metastatic lesions in patients who have completed prior whole brain radiation therapy

Acoustic Neuroma (Vestibular Schwanoma)

- Radiosurgery avoids the risk of facial nerve injury.
- Hearing is preserved in 50-75% of patients who have useful hearing prior to treatment
- Radiosurgey is most effective for tumors less than 3cm diameter but can be a reasonable alternative for larger tumors in older patients with significant co-morbidities.

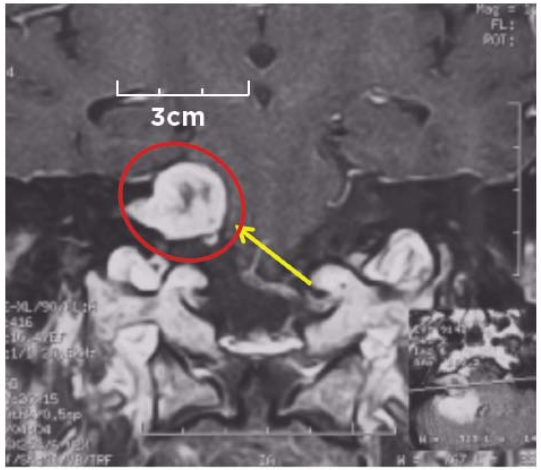

Acoustic neuroma causing brainstem compression

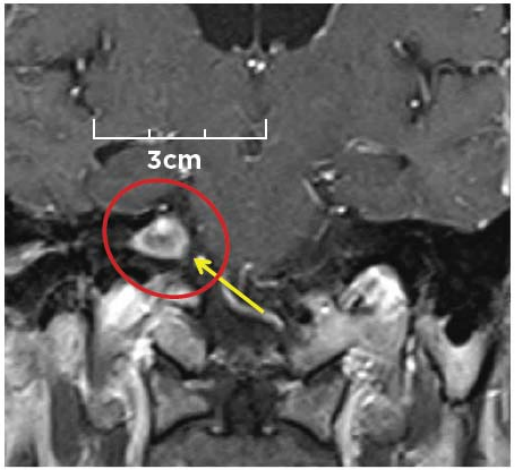

90% Decrease in tumor size and resolution of brainstem compression 11 years after treatment

Trigeminal Neuralgia

- For patients with severe facial pain
- High dose radiation to trigeminal nerve at root entry
- Pain relief 3-4 weeks, 85% of patients see complete relief
- Can be used in conjunction with percutaneous needle procedures or open skull neurosurgery for microvascular decompression

Arteriovenous Malformations (AVM's)

- Obliteration of the AVM after Gamma Knife radiosurgery usually occurs over a time period of three to five years.
- Approximately 75% of patients will achieve complete obliteration within three to five years of treatment.
- Obliteration rates range between 60% for lesions greater than 3 cm in diameter to around 95% for lesions less than 1 cm in diameter, with the option for re-treatment after three to five years in patients with residual AVM.

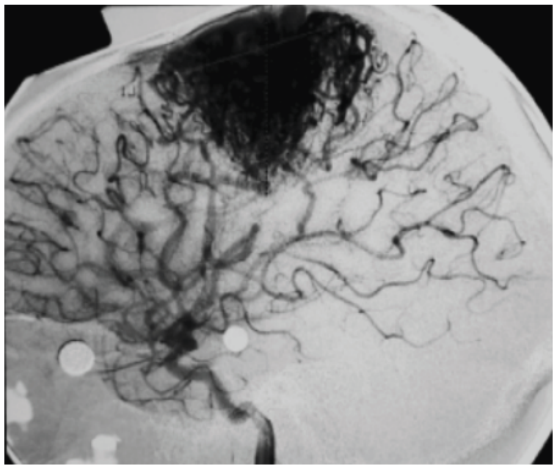

Pretreatment Angiogram

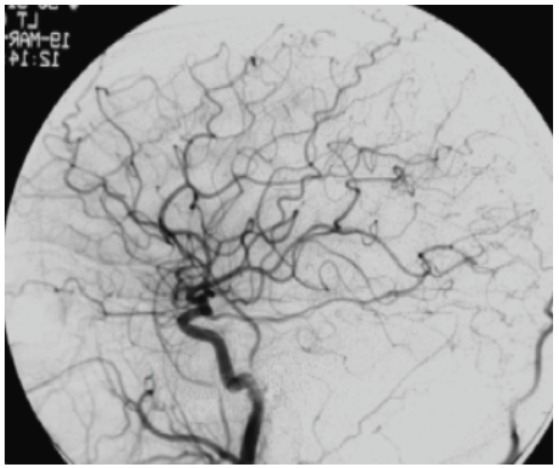

36 months after treatment

Other Brain Tumors

- Can be treated with the Gamma Knife ICON including meningioma, glioblastoma multiforme (GBM), astrocytoma, pituitary adenomas and skull base tumors.

Tremor

- May be used to treat patients with disabling hand tremor due to Benign Essential Tremor, Parkinson's disease or Multiple Sclerosis.
- Target tremor cells within the thalamus
- Excellent or good relief of tremor in 80% of patients

References:

1. McDonald D, Schuler J, Takacs I, Peng J, Jenrette J, Vanek K. Comparison of radiation dose spillage from the Gamma Knife Perfexion with that from volumetric modulated arc radiosurgery during treatment of multiple brain metastases in a single fraction. *J Neurosurg* 2014; **121**(Suppl): 51-9

Gamma Knife ICON Treatment Team

NEUROSURGEONS:

Peter Basta, MD

Geoffrey Blatt, MD

Jonathan Chilton, MD
Medical Director

Jayson Nell, MD

William Rosenberg, MD

RADIATION ONCOLOGISTS:

David Shaeffer, MD

John Sheldon, MD

NEURO-OTOLARYNGOLOGISTS: (NEURO ENTS)

Robert Cullen, MD

Joseph Ursick, MD

NEURO ONCOLOGIST:

Amandeep Kalra, MD

STEREOTACTIC RADIOSURGERY COORDINATOR:

Sirena M. Shaneyfelt, RN, MSN, OCN

NEURO INTERVENTIONAL RADIOLOGIST:

Graham Lee, MD

Ryan Hegg, MD

MEDICAL PHYSICIST:

Bob Gilliam, MS

Eddie Dickerson, MS

NURSE SPECIALIST:

Jeff Chung, RN

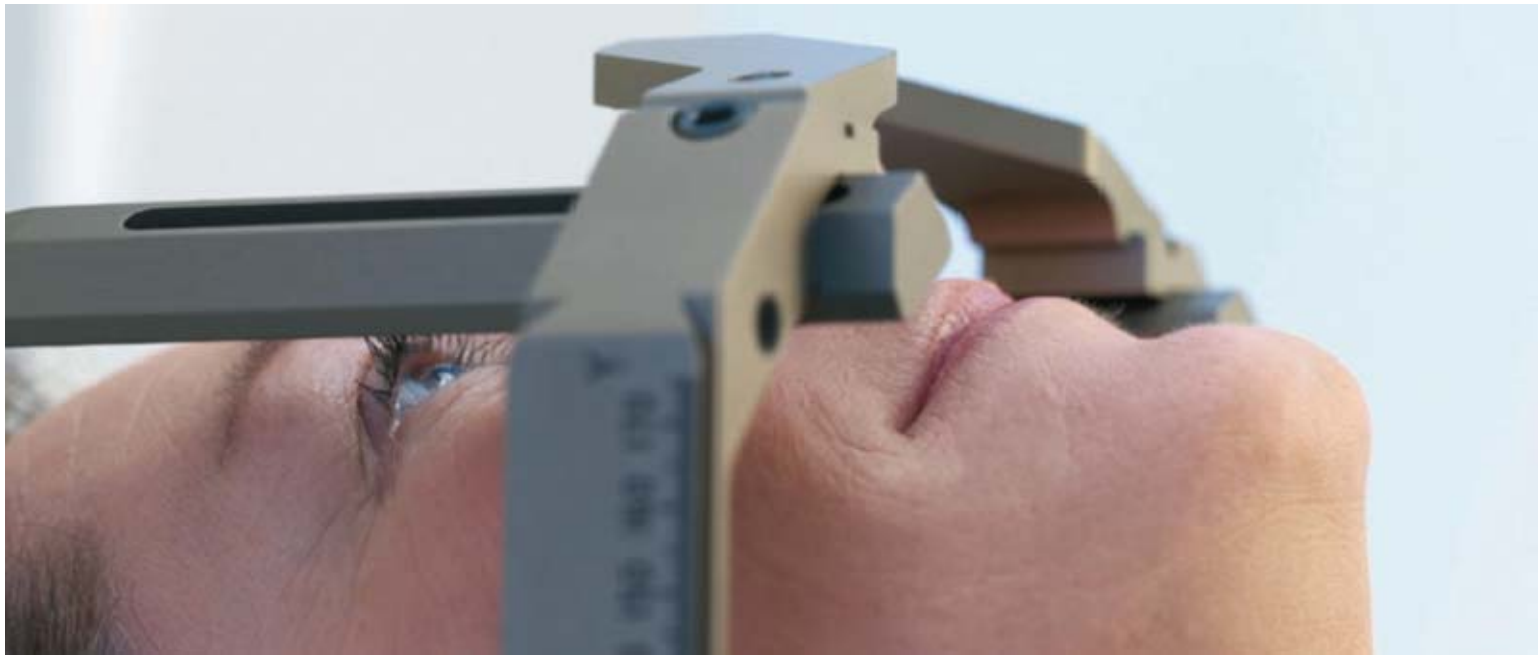

Sample Patient Information Guide

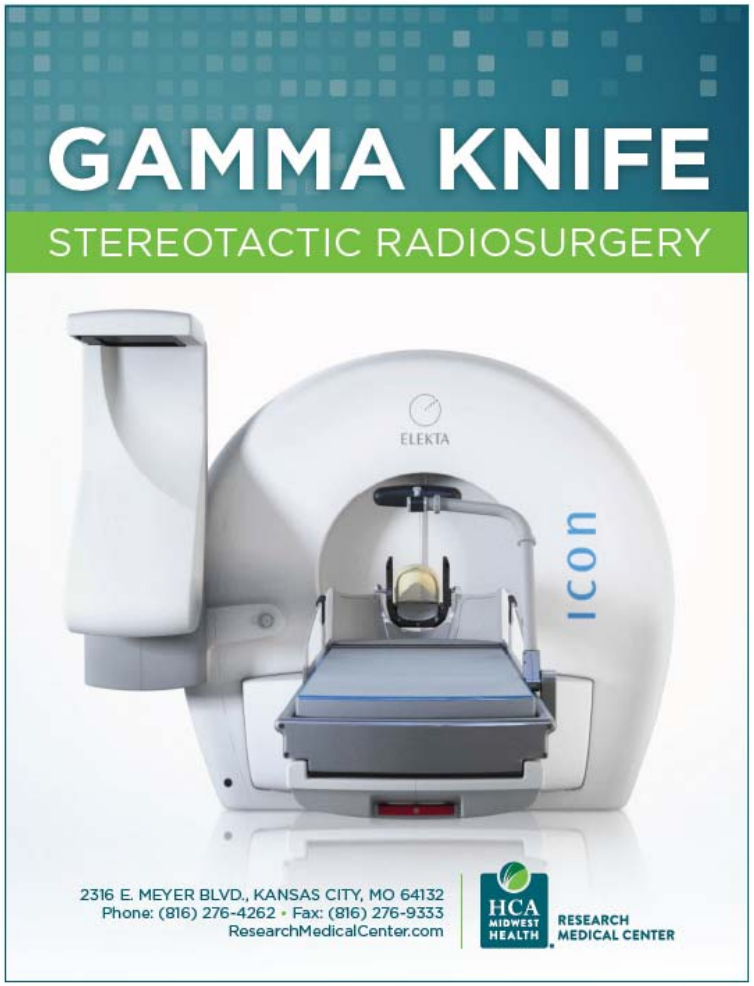

1.5

To refer a patient, please call Midwest Gamma Knife Center:

816 276 4262

http://researchmedicalcenter.com/service/about-gamma-knife

HCA®